

Histological Alterations in Liver and Kidney of Javanese Medaka (*Oryzias javanicus*, Bleeker 1854) Exposed to Sublethal Concentration of Herbicide Diuron

Nur Amiera Kamarudin, Syaizwan Zahmir Zulkifli*, Fatin Zahidah Abdul Aziz and Ahmad Ismail

Department of Biology, Faculty of Science, Universiti Putra Malaysia, 43400 Serdang, Selangor, Malaysia

ABSTRACT

Diuron has been substantially used in different parts of the world as an herbicide and as a bioactive ingredient in antifouling paint. However, knowledge on the toxicity of Diuron that could adversely affect non-targeted aquatic organisms, especially fish; is still deficient. Therefore, this study was conducted to determine the possible sublethal effects of phenyl-urea herbicide Diuron at the cellular level of the liver and kidneys of an adult Javanese medaka (*Oryzias javanicus*), which has been used as the novel model organism. In the present study, histological assessment was carried out using the hematoxylin and eosin (H&E) staining protocol where the samples were preserved in 10% buffered formalin and sectioned into 5 μm thickness. The 210 samples used contained a range of Diuron concentrations comprising 1 $\mu\text{g/L}$, 50 $\mu\text{g/L}$, 100 $\mu\text{g/L}$, 500 $\mu\text{g/L}$ and 1000 $\mu\text{g/L}$; which also included the control treatments. Semi quantitative analysis revealed that liver and kidney tissues exposed at higher concentrations (500 $\mu\text{g/L}$ and 1000 $\mu\text{g/L}$) showed significantly moderate to severe deformities and mild lesion alterations were already shown even at a

lower concentration of Diuron exposure (1.0 $\mu\text{g/L}$), as compared to the control treatment of dechlorinated water ($p < 0.05$). The most evident and observable severity of the lesions in the liver were due to vacuolation, congestion and nodule necrosis while the kidney showed tubule degeneration, glomerulus shrinkage and hemosiderin. Hence, this study further reinforces the documentary evidence in developing *O.*

ARTICLE INFO

Article history:

Received: 03 December 2018

Accepted: 30 January 2019

Published: 24 July 2019

E-mail addresses:

nuramiera2510@gmail.com (Nur Amiera Kamarudin)

syaizwan@upm.edu.my (Syaizwan Zahmir Zulkifli)

zahidah_aziz@yahoo.com (Fatin Zahidah Abdul-Aziz)

aismail@upm.edu.my (Ahmad Ismail)

* Corresponding author

javanicus as the novel model organism to represent tropical regions in aquatic toxicological studies. Although the level of Diuron in Malaysia is unthreatening, this emerging hazardous chemical can seriously affect the aquatic ecosystem in later years.

Keywords: Diuron, histology, Javanese medaka, kidney, liver, sublethal

INTRODUCTION

Globally, herbicides are phytotoxic chemicals that have relatively played a pivotal role in the agriculture sector by eliminating or destroying unwanted vegetation in crop and plantation areas. Since the 1960s, Malaysia has been a country, which has flourished its agricultural economy with various plantation crops such as oil palms and rubber plantations (Istikomah & Rahman, 2015). These agricultural developments coincide with the use of herbicides. De et al. (2014) reported that the worldwide use of herbicide contributed to almost 48% of the total pesticide usage and it was represented as the most rapidly growing section in the past three decades in the pesticide industry. Although the use of herbicides is focusing on the killing of weeds in the agriculture industry, it unintentionally affects aquatic organisms, since it can be found in water bodies as a toxic pollutant.

Diuron is one of the most heavily used herbicides around the world as it is easily taken up by the plant through the root system from the soil solution (Moncada, 2004). Giacomazzi and Cochet (2004) had affirmed that Diuron was mostly used to control the annual grassy weeds and broadleaf weeds in the pre- and post-emergent stages. In addition, Ali et al. (2014) and Hanapiah et al. (2017) reported that the other sources of Diuron found in the coastal areas of Malaysia were from the antifouling paint applied underneath boats and ships which caused contamination in the coastal areas of Klang, Johor, and Kemaman.

The runoff sedimentation, leaching, spring drift or accidental spills of Diuron from the plantation area into ecosystems such as rivers, can indirectly affect freshwater vertebrates such as tilapia and goldfish (Hanapiah et al., 2018; Saglio & Trijasse, 1999) and invertebrates such as water fleas and freshwater snails (López-Doval et al., 2014). Also, the level of toxicity reported for fish and aquatic invertebrates is considered moderately toxic if the Diuron's acute median lethal concentration (LC50) is between 1 mg/L to 10 mg/L, based on the Wildlife Toxicity Category. Moreover, Abushaala et al. (2015) also reported that the LC50 value of Diuron on brine shrimp (*Artemia salina*) ranged between 6 mg/L to 24 mg/L. Also, Moncada (2004) reported that, due to the long half-life, Diuron could contaminate groundwater as it was persistent and mobile in the soil.

There are several studies related to Diuron that have shown how it can cause mortality at higher concentrations, but exposure at lower concentrations causes more toxicity effects in the whole body system over a longer period of time. These sublethal effects can affect the

neurotransmitter, immune response, physiological, morphological as well as reproduction (López-Doval et al., 2014). The objective of this study is to observe the impairment and abnormalities in the cell and tissue structures of the liver and kidney of Javanese medaka (*Oryzias javanicus*) as a novel model organism. The distinctive characteristic of the Javanese medaka as part of the euryhaline species, is the ability to represent the wide range of salinity in a contaminated aquatic ecosystem (Mohamat-Yusuff et al., 2018). Furthermore, the selected endpoints of Diuron exposure in Javanese medaka have not been studied recently or to this date.

MATERIALS AND METHODS

Experimental Design

This study was conducted using adult *O. javanicus*, sized between 3-4 cm (n=210; including control treatments) obtained from Sungai Pelek, Bagan Lalang, Selangor, Malaysia. The fish was acclimatised in freshwater environment for 6 months in Medaka's Laboratory in the Department of Biology, Faculty of Science, Universiti Putra Malaysia, before the experiments were conducted in the Ecotoxicology Laboratory. During the acclimatisation period, the water tanks used to keep the *O. javanicus* were timely changed with dechlorinated water and maintained in a recirculating water flow-through system.

To maintain the *O. javanicus* in the laboratory, we followed the protocols as suggested by Aziz et al. (2017). The water pH and temperature values were maintained and monitored the same way as the experimental conditions. All *O. javanicus* were fed with freshly cultured nauplii of brine shrimp, while the *Artemia salina* were cultured as explained by Abushaala et al. (2015) and were fed with commercial diet fish pallet three times per day. The photo-period was also maintained on 14 h L: 10 h D cycle. A multi-parameter device (YSI Model MPS 556) was used to measure water parameters such as temperature, pH, and dissolved oxygen and the mean results recorded (\pm SD) were $25 \pm 1^\circ\text{C}$, 7.0 ± 0.5 , and 6.9 ± 0.6 mg/L, respectively.

The experiments were conducted for three weeks (21 days) with three replicates of seven treatments (total of 21 tanks) including the dechlorinated water control and solvent (DMSO) water control sets. Ten individuals of *O. javanicus* were individually stocked in each treatment tanks in a static water system; which were changed regularly to reduce the build-up of ammonia from the feces which subsequently were replaced back into the tank with the same volume removed and with the same treatment concentration in each tank. Diuron was purchased from Sigma-Aldrich Diuron ($\geq 98\%$) in powder form and the stock solution was prepared using DMSO as a solvent prior to the experiment. Diuron concentrations were determined from a series of preliminary tests; namely 1 $\mu\text{g/L}$, 50 $\mu\text{g/L}$,

100 µg/L, 500 µg/L and 1000 µg/L, dechlorinated water controls, and solvent controls. The water parameters were monitored and checked regularly throughout the experiments.

Tissues Preparation and Histology

After three weeks of exposure to sublethal herbicide Diuron concentrations, the fish were killed immediately. The whole body of the fish was fixed in Davidson's solution for 24 hours and transferred into 10% buffered formalin. Histological assessment was carried out using the Hematoxylin and Eosin (H&E) staining protocol and sectioned at 5 µm thicknesses. This method is also guided by Johnson et al. (2009) through the OECD guidelines for the fish histopathology analysis by United States Environmental Protection Agency (US EPA, 1996) and Bernet et al. (2001). The histopathological changes in tissues were examined in randomly selected sections from each organ of each fish. The mean prevalence of each histological parameter was categorised as none (0), mild (1, < 25% of sections), moderate (2, 25 – 50% of sections) and severe (3, >50% of sections) (Mishra & Mohanty, 2008; Korkmaz et al., 2009). The histological treatments in the tissues were photographed using Leica Histology Microscope with a colour camera, which was connected directly to a monitor using a Leica's Application Suite. Statistical analyses were performed using statistical package of SPSS 22.0 for Windows. Differences among the treated group were analysed using a one-way analysis of variance (ANOVA) followed by Duncan test (Korkmaz et al., 2009).

RESULTS AND DISCUSSIONS

Table 1 summarises the histopathological analyses of the liver and kidney of *O. javanicus* for the control and sublethal Diuron samples with the micrograph of tissue images captured in Figure 1 and Figure 2. The hepatocytes and other cells of the liver in both control groups were normal and systematically arranged. The liver tissues showed moderate changes starting at a concentration of 100 µg/L (Figure 1(b)) of Diuron while the kidney tissues showed moderate changes at a lower concentration of 50 µg/L (Figure 2(b)). More severe changes can be observed when kidney tissues were exposed to higher concentrations of Diuron which resulted in tubule degeneration, glomerulus, shrinkage, and hemosiderin which affected more than 50% of the tissue; (Figure 2(c)) as compared to the liver tissues which was moderately changed exhibiting only 25%-50% of the tissues affected by vacuolation of hepatocytes, congestion and nodule necrosis (Figure 1(c)).

This study presented the results relevant to the sublethal effects of herbicide Diuron on *O. javanicus* with reference to tissue histology analyses. These histopathological alterations generally represented the stress-related outcomes of fish tissues triggered by a variety of

environmental factors (Harper & Wolf, 2009). The present study showed the important general effects to the liver organ; such as vacuolation, congestion, and nodule necrosis; in all the treatment groups. These non-specific hepatic lesions in organisms have been reported due to exposure to sub-toxic concentration of pesticides and heavy metals (Cengiz & Unlu, 2003). The liver carries out essential body function as the target organ due to its large blood supply that causes noticeable toxicant exposure, accumulation, clearance function and its pronounced metabolic activity (Mohamed, 2009). Moreover, based on the study by Olurin et al. (2006), the exposure to a wide range of aquatic pollutants such as herbicides and steroid hormones reportedly caused hepatic tissue alterations in fishes. The observations recorded in the present study are similar to that reported by several authors, e.g. Blahova et al. (2014) and Sharma and Sharma (2016). Histopathological alterations of the liver tissue structures in fish can be used as biomarkers to detect changes in the quality of the aquatic ecosystem thus revealing the damages that were induced by xenobiotics in an organism at the cellular and tissue levels (Mela et al., 2013). Several other studies were conducted using wild fish and the results showed significant histological lesions especially in the liver, which indicated that the fishes are living under stressful environmental conditions (Abdel-Moneim et al., 2012; Camargo et al., 2007; Paulo et al., 2012).

In the present study, tubule degeneration, glomerulus, shrinkage, and hemosiderin were observed in the histological alterations of kidney tissue structures after being exposed to different concentrations of sublethal Diuron. The kidney proved to be more sensitive towards Diuron exposure compared to the liver. This is due to the fact that the kidney is the primary organ for water elimination and efficient in ion reabsorption mechanism to minimise ion loss (Salamat & Zarie, 2012). The deformities present suggested that Diuron enters the kidney and disrupts their normal function by histopathological alteration in the kidney tissues (Sharma & Sharma, 2009). Consequently, the necrosis of the renal tubules affects the metabolic activities and promotes metabolic abnormalities. Similar results were obtained by other studies with herbicide treatments as seen in Kannan and Kathiresan (2002), Dumitrescu et al. (2010), and Devasigamani (2015).

The severe effects on the kidney are more severe and prominent as compared to the liver even though they work together to remove the toxic substances from the body. This is due to the important role the kidney plays as one of the first organs that can be affected by contaminants in water polluted with the harmful materials (Thophon et al., 2003). Although these renal alterations alone can provide evidence of toxic exposure, the pathological changes seen in combination with other organs could provide stronger indications of xenobiotic effects (Rhodes et al., 1987).

Table 1
Histopathologic analyses of Javanese medaka (Oryzias javanicus) exposed to sublethal Diuron during 3 weeks (n=36)

Tissues and histopathology	Diuron concentration (µg/L)					
	Control	1	50	100	500	1000
Replicate						
Liver						
Vacuolation; Congestion; Nodule Necrosis						
1	1	2	3	3	3	3
2	1	2	2	2	3	3
3	1	1	1	3	3	2
4	1	2	2	2	2	3
5	2	1	2	1	3	2
6	1	2	1	1	1	3
Mean	1.17^a	1.67^{ab}	1.83^{ab}	2.00^{ab}	2.50^{abc}	2.67^c
Kidney						
Tubule degeneration; Glomerulus shrinkage; Hemosiderin						
1	1	2	3	3	2	3
2	1	2	2	3	3	3
3	1	1	2	2	3	3
4	2	1	2	3	3	3
5	1	2	3	3	3	3
6	1	1	2	3	3	3
Mean	1.17^a	1.50^{ab}	2.33^{ab}	2.83^{abc}	2.83^{abc}	3.00^c

Note: Score value: none (0), mild (1, < 25% of sections), moderate (2, 25– 50% of sections) and severe (3, >50% of sections)

Remark: Different alphabets indicate a significant difference (p<0.05) between the groups

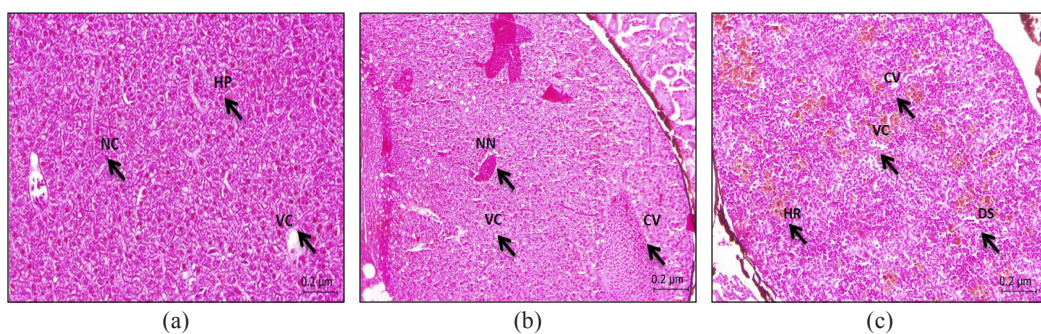


Figure 1. (a) Micrographs of control treatment of Javanese medaka’s liver section (5µm) stained with H&E x 400. (HP) hepatocyte, (NC) hepatocyte nucleus, (VC) hepatic portal vein branch with erythrocytes; (b) micrographs of 100 ppb of Diuron chronic exposure of Javanese medaka’s liver section (5µm) stained with H&E x 400. Congestion of the central vein (CV), vacuolation (VC). The center of granuloma appears necrotic (NN); (c) micrographs of 1000 µg/L of Diuron chronic exposure of Javanese medaka’s liver section (5µm) stained with H&E x 400. Severe vacuolation (VC) shown in the tissue of liver and the brown areas contain hemosiderin (HR). Dilatation and congestion in blood sinusoids (DS); congested central vein with RBC (CV)

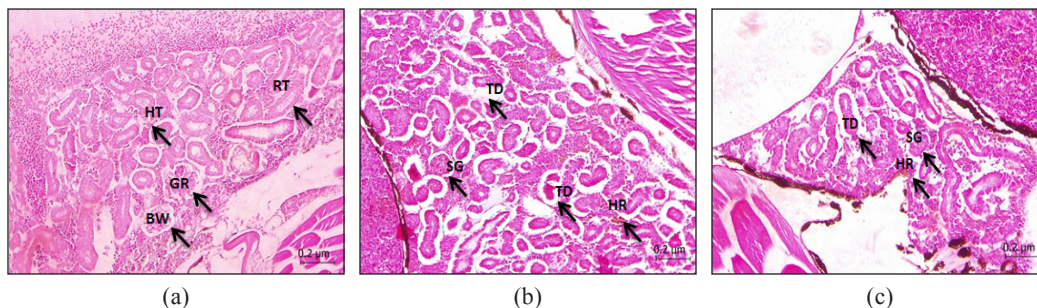


Figure 2. (a) Micrographs of control treatment of Javanese medaka's kidney section (5µm) stained with H&E x 400. Normal kidney, normal tubule (RT), glomerulus (GR), Bowman's capsule (BW) and little amount of hematopoietic tissue (HT); (b) micrographs of 50 ppb of Diuron chronic exposure of Javanese medaka's kidney section (5µm) stained with H&E x 400. Showing glomerulus shrinkage (SG), severe tubule degeneration (TD) and hemosiderin (HR); (c) micrographs of 1000 µg/L of Diuron chronic exposure of Javanese medaka's kidney section (5µm) stained with H&E x 400. Showing glomerulus shrinkage (SG), severe tubule degeneration (TD) and hemosiderin (HR)

CONCLUSIONS

Diuron can be considered a hazardous toxicant to non-targeted organisms in aquatic organisms especially fishes. Fish kidneys appeared to be more sensitive towards Diuron as the lesions and degenerative changes were more severe than in the liver. The observed alterations in the histopathology of vital organs demonstrate the severe adverse effects to chronic exposure of Diuron in the medaka species. Therefore, the chronic exposure may cause severe damages and impairments or even death at higher concentrations of Diuron exposure, which can affect the physiology, life cycle and population of aquatic creatures in the natural environment. Also, this study has reaffirmed the documented evidence in developing Javanese medaka (*O. javanicus*) as the model organism for tropical areas in aquatic toxicological studies.

ACKNOWLEDGEMENTS

This study was supported by the Putra Grant - Putra Graduate Initiative (IPS) (Project Number: GP-IPS/2017/9577500) from Universiti Putra Malaysia and was performed in relation to the JSPS Core-to-Core Program, B. Asia-Africa Science Platforms.

REFERENCES

- Abdel-Moneim, A. M., Al-Kahtani, M. A., & Elmenshawy, O. M. (2012). Histopathological biomarkers in gills and liver of *Oreochromis niloticus* from polluted wetland environments, Saudi Arabia. *Chemosphere*, 88(8), 1028-1035.
- Abushaala, N. M., Zulkifli, S. Z., Ismail, A., Azmai, M. N. A., & Mohamat-Yusuff, F. (2015). Lethal concentration 50 (LC₅₀) and effects of Diuron on morphology of brine shrimp *Artemia salina* (Branchiopoda: Anostraca) nauplii. *Procedia Environmental Sciences*, 30, 279-284.

- Ali, H. R., Arifin, M. M., Sheikh, M. A., Shazili, N. A. M., Bakari, S. S., & Bachok, Z. (2014). Contamination of diuron in coastal waters around Malaysian Peninsular. *Marine Pollution Bulletin*, 85(1), 287-291.
- Aziz, F. Z. A., Zulkiffi, S. Z., Mohamat-Yusuff, F., Azmai, M. N. A., & Ismail, A. (2017). A histological study on mercury-induced gonadal impairment in Javanese medaka (*Oryzias javanicus*). *Turkish Journal of Fisheries and Aquatic Sciences*, 17(3), 621-627.
- Bernet, D., Schmidt, H., Meier, W., Burkhardt-Holm, P., & Wahli, T. (1999). Histopathology in fish: proposal for a protocol to assess aquatic pollution. *Journal of Fish Diseases*, 22(1), 25-34.
- Blahova, J., Modra, H., Sevcikova, M., Marsalek, P., Zelnickova, L., Skoric, M., & Svobodova, Z. (2014). Evaluation of biochemical, haematological, and histopathological responses and recovery ability of common carp (*Cyprinus carpio* L.) after acute exposure to atrazine herbicide. *BioMed Research International*, 2014. <http://dx.doi.org/10.1155/2014/980948>
- Camargo, M. M., & Martinez, C. B. (2007). Histopathology of gills, kidney and liver of a Neotropical fish caged in an urban stream. *Neotropical Ichthyology*, 5(3), 327-336.
- Cengiz, E. I., & Ünlü, E. (2003). Histopathology of gills in Mosquitofish, *Gambusia affinis* after long-term exposure to sublethal concentrations of malathion. *Journal of Environmental Science and Health, Part B*, 38(5), 581-589.
- De, A., Bose, R., Kumar, A., & Mozumdar, S. (2014). *Targeted delivery of pesticides using biodegradable polymeric nanoparticles*. New Delhi: Springer.
- Deivasigamani, S. (2015). Effect of herbicides on fish and histological evaluation of common carp (*Cyprinus carpio*). *International Journal of Applied Research*, 1(7), 437-40.
- Dumitrescu, G., Ciochina, L. P., Voia, S., Dronca, D., & Boca, L. (2010). Histological changes induced in gonads, liver and kidney of zebra fish (*Danio rerio*) under the effect octylphenol (OP). *Scientific Papers Animal Science and Biotechnologies*, 43(1), 484-489.
- Giacomazzi, S., & Cochet, N. (2004). Environmental impact of diuron transformation: A review. *Chemosphere*, 56(11), 1021-1032.
- Hanapiah, M., Zulkiffi, S. Z., Shahrin, M. S., Mohamat-Yusuff, F., Ismail, A., Harino, H., & Inoe, K. (2017). Concentration of antifoulant herbicides, Diuron in the vicinity of Port Klang, Malaysia. *Isu-isu Terkini Penyelidikan Saintifik Sains Marin di Malaysia*, 1, 35-38.
- Hanapiah, M., Zulkiffi, S. Z., Mustafa, M., Mohamat-Yusuff, F., & Ismail, A. (2018). Isolation, characterization, and identification of potential Diuron-degrading bacteria from surface sediments of Port Klang, Malaysia. *Marine Pollution Bulletin*, 127, 453-457.
- Harper, C., & Wolf, J. C. (2009). Morphologic effects of the stress response in fish. *Institute for Laboratory Animal Research Journal*, 50(4), 387-396.
- Istikoma, Q. A., & Rahman, A. A. (2015). The transformation of agriculture based economy to an industrial sector through crowd sourcing in Malaysia. *International Journal of Computer Science and Information Technology Research*, 3(1), 34-41.

- Johnson, R., Wolf, J., & Braunbeck, T. (2009). *OECD guidance document for the diagnosis of endocrine-related histopathology of fish gonads*. Paris, France: Organization for Economic Co-operation and Development.
- Kannan, C., & Kathiresan, R. M. (2002). Herbicide control of water hyacinth and its impact on fish growth and water quality. *Indian Journal of Weeds Science*, 34(1-2), 92-95.
- Korkmaz, N., Cengiz, E. I., Unlu, E., Uysal, E., & Yanar, M. (2009). Cypermethrin-induced histopathological and biochemical changes in Nile tilapia (*Oreochromis niloticus*), and the protective and recuperative effect of ascorbic acid. *Environmental Toxicology and Pharmacology*, 28(2), 198-205.
- López-Doval, J. C., Poquet, M., & Muñoz, I. (2014). Sublethal effects of the herbicide diuron on the freshwater snail *Physella acuta*. *Limnetica*, 33(1), 205-215.
- Mela, M., Guiloski, I. C., Doria, H. B., Randi, M. A. F., de Oliveira Ribeiro, C. A., Pereira, L., Maraschi, A. C., Prodocimo, V., Freire, C. A., & de Assis, H. S. (2013). Effects of the herbicide atrazine in neotropical catfish (*Rhamdia quelen*). *Ecotoxicology and Environmental Safety*, 93, 13-21.
- Mishra, A. K., & Mohanty, B. (2008). Acute toxicity impacts of hexavalent chromium on behavior and histopathology of gill, kidney and liver of the freshwater fish, *Channa punctatus* (Bloch). *Environmental Toxicology and Pharmacology*, 26(2), 136-141.
- Mohamat-Yusuff, F., Sarah-Nabila, A. G., Zulkifli, S. Z., Azmai, M. N. A., Ibrahim, W. N. W., Yusof, S., & Ismail, A. (2018). Acute toxicity test of copper pyriithione on Javanese medaka and the behavioural stress symptoms. *Marine Pollution Bulletin*, 127, 150-153.
- Mohamed, F. A. S. (2009). Histopathological studies on *Tilapia zillii* and *Solea vulgaris* from Lake Qarun, Egypt. *World Journal of Fish and Marine Sciences*, 1(1), 29-33.
- Moncada, A. (2004). *Environmental fate of diuron: Environmental monitoring branch, Department of Pesticide Regulation, Sacramento, California*. Retrieved March 1, 2018, from <https://www.cdpr.ca.gov/docs/emon/pubs/fatememo/diuron.pdf>
- Olurin, K. B., Olojo, E. A. A., Mbaka, G. O., & Akindele, A. T. (2006). Histopathological responses of the gill and liver tissues of *Clarias gariepinus* fingerlings to herbicide, glyphosate. *African Journal of Biotechnology*, 5(24), 2480-2487.
- Paulo, D. V., Fontes, F. M., & Flores-Lopes, F. (2012). Histopathological alterations observed in the liver of *Poecilia vivipara* (Cyprinodontiformes: Poeciliidae) as a tool for the environmental quality assessment of the Cachoeira River, BA. *Brazilian Journal of Biology*, 72(1), 131-140.
- Rhodes, L. D., Myers, M. S., Gronlund, W. D., & McCain, B. B. (1987). Epizootic characteristics of hepatic and renal lesions in English sole, *Parophrys vetulus*, from Puget Sound. *Journal of Fish Biology*, 31(3), 395-407.
- Saglio, P., & Trijasse, S. (1998). Behavioral responses to atrazine and diuron in goldfish. *Archives of Environmental Contamination and Toxicology*, 35(3), 484-491.
- Salamat, N., & Zarie, M. (2012). Using of fish pathological alterations to assess aquatic pollution: A review. *World Journal of Fish and Marine Sciences*, 4(3), 223-231.

- Sharma, K. K., & Sharma, J. (2016). Histopathological alterations in the liver, gills and kidneys of fish *Labeo rohita* after the exposure of endosulfan and lindane. *International Journal of Advances in Science Engineering and Technology*, 4(3), 236-239.
- Thophon, S., Kruatrachue, M., Upatham, E. S., Pokethitiyook, P., Sahaphong, S., & Jaritkhuan, S. (2003). Histopathological alterations of white seabass, *Lates calcarifer*, in acute and subchronic cadmium exposure. *Environmental Pollution*, 121(3), 307-320.
- United States Environmental Protection Agency. (1996). *Ecological effects test guidelines: Fish acute toxicity test, freshwater and Marine, OPPTS 850.1075*. Retrieved January 19, 2017, from <https://19january2017snapshot.epa.gov/sites/production/files/2015-07/documents/850-1075.pdf>